



# MR-guided biopsy and focal therapy: new options for prostate cancer management

Fuad F. Elkhoury, Demetrios N. Simopoulos, and Leonard S. Marks

## Purpose of review

Options for prostate cancer management are rapidly expanding. The recent advent of MRI technology has led to guided prostate biopsies by radiologists working in-bore or by urologists using MR/US fusion technology. The resulting tumor visualization now provides the option of focal therapy. Currently available are highly directed energies – focused ultrasound (HIFU), cryotherapy, and laser – all offering the hope of curing prostate cancer with few side effects.

## Recent findings

MRI now enables visualization of many prostate cancers. MR/US fusion biopsy makes possible the targeted biopsy of suspicious lesions efficiently in the urology clinic. Several fusion devices are now commercially available. Focal therapy, a derivative of targeted biopsy, is reshaping the approach to treatment of some prostate cancers. Focal laser ablation, originally done in the MRI gantry (in-bore), promises to soon become feasible in a clinic setting (out-of-bore) under local anesthesia. Other focal therapy options, including HIFU and cryotherapy, are currently available. Herein are summarized outcomes data on focal therapy modalities.

## Summary

MRI-guided biopsy is optimizing prostate cancer diagnosis. Focal therapy, an outgrowth of guided biopsy, promises to become a well tolerated and effective approach to treating many men with prostate cancer while minimizing the risks of incontinence and impotence from radical treatment.

## Keywords

focal laser ablation, focal therapy, fusion biopsy, prostate cancer, targeted biopsy

## INTRODUCTION

In 2017, more than 160 000 men will be diagnosed with prostate cancer, the majority by trans-rectal ultrasound (TRUS) guided biopsy [1,2]. However, TRUS-guided biopsy, dating from the 1980s, often underestimates actual disease because of the inability of ultrasound to distinguish malignant from benign prostatic tissue [3,4]. In fact, TRUS-guided biopsy fails to detect the true prostate cancer pathology 44% of the time, according to one large Surveillance, Epidemiology, and End Results database analysis [5].

Prostate MRI enables visualization of many lesions suspicious for cancer, and MRI-guided biopsy techniques allow for targeting of these lesions to improve cancer detection [6]. By translating targeted biopsy into focal therapy, urologists can now offer specific, limited treatment of prostate cancer, thus avoiding the lifestyle consequences of radical therapy. Herein, we review the role of MR-guided prostate biopsy technology in cancer detection and the growing use of various focal therapy modalities for the management of prostate cancer.

## PROSTATE MRI

Prostate visualization with MRI was first reported in 1983 by Hricak *et al.* [7] who showed that malignant prostate tissue had higher signal intensity than benign tissue. Since then, technological advancements and growing experience have led to the development of multiparametric MRI (mpMRI), which combines T2-weighted images with diffusion-weighted images and dynamic contrast enhancement. This allows for anatomic and functional assessment of the prostate and improves tumor detection and characterization. Furthermore,

UCLA Department of Urology, David Geffen School of Medicine, Los Angeles, California, USA

Correspondence to Leonard S. Marks, MD, UCLA Department of Urology, David Geffen School of Medicine, Wasserman Bldg, Suite 331, UCLA Medical Plaza, Los Angeles, CA 90095, USA.

Tel: +1 310 794 8659; fax: +1 310 794 8653;

e-mail: lmarks@mednet.ucla.edu

**Curr Opin Urol** 2017, 27:000–000

DOI:10.1097/MOU.0000000000000471

## KEY POINTS

- MR/US fusion prostate biopsy allows for the targeting of suspicious regions, template-mapping for systematic sampling, and tracking of cancer foci over time, all functions not previously possible with US-guided biopsy.
- Targeted biopsy using MR/US fusion improves detection of clinically significant prostate cancer. Highly suspicious regions of interest on MRI are likely to contain cancer on targeted biopsy.
- Focal therapy, including focal laser ablation, HIFU, and cryotherapy, aims to ablate the index cancer lesion and preserve continence and erectile function, providing a new alternative for many men with prostate cancer.

the Prostate Imaging-Reporting and Data System (PI-RADS) has standardized reporting terminology and streamlined communication of risk assessment between radiologists and urologists [8].

Prostate MRI has been shown to improve the accuracy of prostate cancer diagnosis, with increased detection of high-grade disease and extra-prostatic extension [9,10]. A recent meta-analysis of almost 3900 patients found that MRI has a sensitivity of 89% and specificity of 73% for detecting prostate cancer [11]. The American Urological Association has endorsed use of MRI-guided biopsy in the repeat biopsy setting [12], but recently Level 1 evidence confirming its value in a first-biopsy setting has also been presented [13]. According to the PROMIS study, mpMRI has a 93% sensitivity and 89% negative predictive value for detecting clinically significant prostate cancer [13]. Importantly, MRI revealed all instances of Gleason 4 lesions. As MRI technology improves, prostate lesion detection will become more accurate and dependable, enhancing diagnostic and therapeutic capabilities.

## MRI-GUIDED TARGETED PROSTATE BIOPSY

Use of MRI to identify and guide biopsy of suspicious lesions has brought ‘targeted prostate biopsy’ into present-day parlance. Several targeted biopsy approaches have emerged: direct ‘in-bore’ biopsies, cognitive fusion biopsy, and MRI/US fusion biopsy.

### In-bore biopsy

The use of MRI to guide prostate biopsy to a region of interest (ROI) was first performed in 2000 within an

MRI scanner (in-bore) via a trans-perineal approach [14]. Today, either a transperineal or a transrectal approach is used for in-bore biopsy, which is performed by radiologists. The first MRI scan is performed to identify the ROI and for biopsy planning, and a subsequent image is obtained for each biopsy core to confirm needle position. A theoretical advantage of the in-bore approach is a reduction in number of biopsy cores, because cores are only taken from the ROI. However, in-bore biopsy is lengthy and resource-intensive, and sedation is often required. Also, template mapping and tracking biopsies are not possible with the in-bore approach, potentially missing significant cancer elsewhere in the prostate not visible on MRI.

### Cognitive fusion biopsy

Because the logistical and diagnostic limitations of in-bore biopsy, MRI-guided biopsy outside of the MRI scanner (out-of-bore) has become increasingly adopted. Cognitive fusion is the simplest of the out-of-bore approaches. It relies on the urologist to review the MRI images and mentally overlay, or ‘cognitively fuse’, the MRI to the real-time TRUS to biopsy the MR-identified region of interest. The advantage of cognitive fusion is that no fusion device is required. However, this approach is operator dependent. The differing planes between oblique TRUS images and axial MRI images increase potential inaccuracies of cognitive fusion. Further, template mapping and tracking of biopsy sites are not possible with this approach, compromising its value for active surveillance and repeat biopsies.

### MRI/US fusion biopsy

In the clinic setting under local anesthesia, MR/US fusion uses image-fusion software to overlay the ROI detected on MRI onto the real-time TRUS images at the time of biopsy. Fusion biopsy resolves many of the logistical difficulties of in-bore biopsy and the operator-dependency of cognitive fusion biopsy. MR/US fusion biopsy is relatively quick compared to the in-bore approach and employs the usual clinic workflow. Table 1 presents the MR/US fusion devices currently in use in the United States and abroad. The advantages of MR/US fusion biopsy have made that approach the choice of most urologists and the most thoroughly studied [15].

## TARGETED PROSTATE BIOPSY – OUTCOMES AND APPLICATIONS

Using MRI guidance, targeted biopsy has bolstered the urologist’s armamentarium for diagnosing

**Table 1.** MRI/US fusion devices commonly used in USA and internationally

Device	Co-registration methods	TRUS probe movement	Biopsy approach	Comments
Artemis (Eigen, USA)	Position-encoded joints on robotic arm	In/out and rotational movement only (fixed to mechanical arm)	Transrectal	Robotic arm stabilizes the probe Training required to learn software and manual manipulation of TRUS biopsy via mechanical arm
BioJet (GeoScan Medical, USA)	Position-encoded joints on robotic arm	In/out and rotational movement only	Transrectal or transperineal	TRUS-probe mounted to angle-sensing mechanical arm that exports information on probe position to workstation.
BiopSee (Medcom, Germany)	Position-encoded joints on robotic arm	In/out and rotational movement only (fixed to mechanical arm)	Transperineal	Biopsy setup similar to brachytherapy; TRUS probe guides transperineal biopsies Most recently FDA approved in 2017
Real-Time Virtual Sonography (Hitachi, Japan)	Electromagnetic field generator	Freely movable by hand	Transrectal or transperineal	Primarily used in Japan; little studied elsewhere
UroNav (Invivo, USA)	Electromagnetic field generator	Freely movable by hand	Transrectal	Familiar freehand TRUS approach
Urostation (Koelis, France)	Software image-based tracking	Freely movable by hand	Transrectal	Most common platform in Europe Relies on 3D TRUS image tracking without any beam-tracking external hardware.

prostate cancer. The importance of MRI-guided targeted biopsy has been demonstrated in two large prospective studies published in the past few years [16,17<sup>22</sup>]. Using different MRI/US fusion devices [16,17<sup>22</sup>], both groups compared within patients the yield of biopsies targeting MRI-visible lesions versus systematic TRUS-guided biopsies. Similar conclusions were reached: targeting allows detection of more clinically significant cancers than systematic sampling alone. In both studies, targeted biopsy yield was directly related to MRI grade of the ROI.

A recent meta-analysis by Valerio *et al.* [18] reviewed 15 studies comparing MRI-targeted biopsy to systematic TRUS-guided biopsy and found that targeted biopsy detects more clinically significant prostate cancer than systematic biopsy. Targeted fusion biopsy is much more efficient than systematic biopsy, requiring a putative 32 less cores than TRUS biopsy to diagnose one significant prostate cancer. Cumulatively, these results compelled the American Urological Association and Society of Abdominal Radiology in 2016 to issue a joint 'White Paper' endorsing MRI-guided biopsy in the repeat biopsy setting [12<sup>22</sup>].

### Tracking biopsy using MR/US fusion

MR/US fusion technology provides the ability to track with millimeter accuracy the location of a cancerous site from one biopsy session to a later resampling session [19]. Thus, longitudinal monitoring of specific sites, suspicious or cancerous, to

assess for appearance or progression of a lesion, is a key function of fusion biopsy using electronic devices. The use of tracking biopsy in active surveillance programs appears to be a substantial advance in this rapidly growing management strategy [20,21].

Implications for tracking technology in active surveillance were highlighted by Chang *et al.* who studied the use of this new method to re-biopsy previously positive sites. Tracking detected more clinically significant disease than systematic biopsy alone, disqualifying many men from active surveillance [22<sup>22</sup>]. Fifty-three percent of upgrades were detected by tracking alone, and 23% of men with Gleason score 3 + 4 lesions were disqualified from active surveillance when tracking biopsy detected Gleason score at least 4 + 3 disease. Tracking precision was recently confirmed by Palapattu *et al.* [23<sup>22</sup>] employing sophisticated molecular markers. Re-biopsy of specific tumor sites 1 year after initial diagnostic biopsy identified the same cell clones in 96% of men at the second biopsy. Tracking technology is a major advantage of using MR/US fusion technology, particularly in men on active surveillance.

### MR/US fusion biopsy in active surveillance

The ability to identify appropriate active surveillance candidates and to exclude others is enhanced by MR/US fusion biopsy. In a study from UCLA, 36% of men, who appeared to be good candidates for A.S. by conventional biopsy, were found to have high-risk lesions when subjected to MRI-guided biopsy

[21]. MR/US fusion biopsy has also been shown to improve concordance with whole-organ pathology compared to TRUS-guided biopsy [9,24,25]. Eight recently published studies where MRI-guided confirmatory biopsies were used in active surveillance found that the rate of upgrading with MRI-guided biopsy was 26–42%, substantially higher than the 2.5–28% range with US-guided biopsy [22<sup>a</sup>,26–34]. Taken altogether, these findings demonstrate that MR/US fusion biopsy is more accurate than conventional biopsy for screening and following men considering active surveillance.

## FOCAL THERAPY

Targeted biopsy provides the basis for focal therapy, enabling the new limited treatment to become an effective option for many men with cancers of low-to-intermediate risk.

Focal therapy is the targeted destruction of an index cancer lesion while preserving the surrounding normal, healthy parenchyma. Despite the prevalence of multifocality, the index lesion (the largest cancer focus in the prostate) appears to be responsible for the natural history of that cancer [35–38]. Anatomically distinct prostate cancer metastases have been shown to originate from a single clone of cells in the prostate, rather than from other (insignificant) clones that may be present [39]. Thus, rare exceptions notwithstanding [39], the largest and most de-differentiated lesion (i.e., the index lesion) drives cancer progression, making localized treatment of that specific tumor site a reasonable approach.

### Appropriate patient selection for focal therapy

Patient selection is critical to the efficacy of focal therapy. A 2015 consensus panel deemed men with low-to-intermediate risk prostate cancer suitable for focal therapy [40]. Specifically, those with small, unifocal Gleason score 7 or larger unilateral Gleason score 6 disease are ideal candidates for focal therapy [41]. Additional eligibility criteria include patient life expectancy greater than 10 years, good patient performance status, and cancer diagnosis via MR-guided biopsy or TRUS-guided biopsy with concordant mpMRI [42]. TRUS-guided biopsy alone is insufficient for focal therapy planning.

### Focal therapy options

Focal laser ablation (FLA), cryotherapy, and high-intensity focused ultrasound (HIFU) are the most common focal therapy options available today.

Although other focal treatment modalities have been described [43], these three have been the most robustly studied to date.

### Focal laser ablation

In FLA, cancerous spots are treated by inserting a laser fiber into a prostatic lesion under MR-guidance, either directly (in-bore) or indirectly (via MR/US fusion). Tumor ablation is accomplished via heating tissues enough to cause coagulation necrosis (generally  $>50^{\circ}\text{C}$ ). Both transrectal and transperineal approaches have been used (Table 2). Although usually only the index lesion is targeted, the laser fiber may be repositioned to treat secondary lesions.

Table 2 summarizes the FLA trials published to date. The first FLA trial was reported in 2009 by Lindner *et al.* [44] in which patients under general anesthesia had laser fibers placed transperineally via MR/US fusion guidance. Contrast-enhanced ultrasound was used for real-time thermal and treatment monitoring. Six-month follow-up biopsy revealed 67% of patients were tumor-free at the ablation zone and 50% were tumor-free throughout the prostate. Urinary and sexual side effects were not observed.

Subsequently, FLA was performed in-bore, within the gantry of an MRI unit. This method allows for both direct MR-guided positioning of the laser fiber and real-time MR thermometry and visualization of the treatment zone. In 2014, Oto *et al.* [45,46<sup>aa</sup>] at the University of Chicago first reported in-bore FLA in nine patients done transperineally under conscious sedation, followed by a phase II trial involving 27 patients in 2016. Both studies had encouraging oncologic outcomes on follow-up biopsy at 3, 6, and 12 months post-FLA (see Table 2). Natarajan *et al.* [47<sup>aa</sup>] were among the first to study treatment margins after in-bore FLA and found that biopsies of the ablation margins often contained residual cancer. However, FLA did not impact urinary or sexual function in the studies performed to date (Table 2). Further elucidation of appropriate ablation zone size and safety parameters is underway to supplement the progress from these preliminary FLA trials.

### Focal laser ablation in the clinic

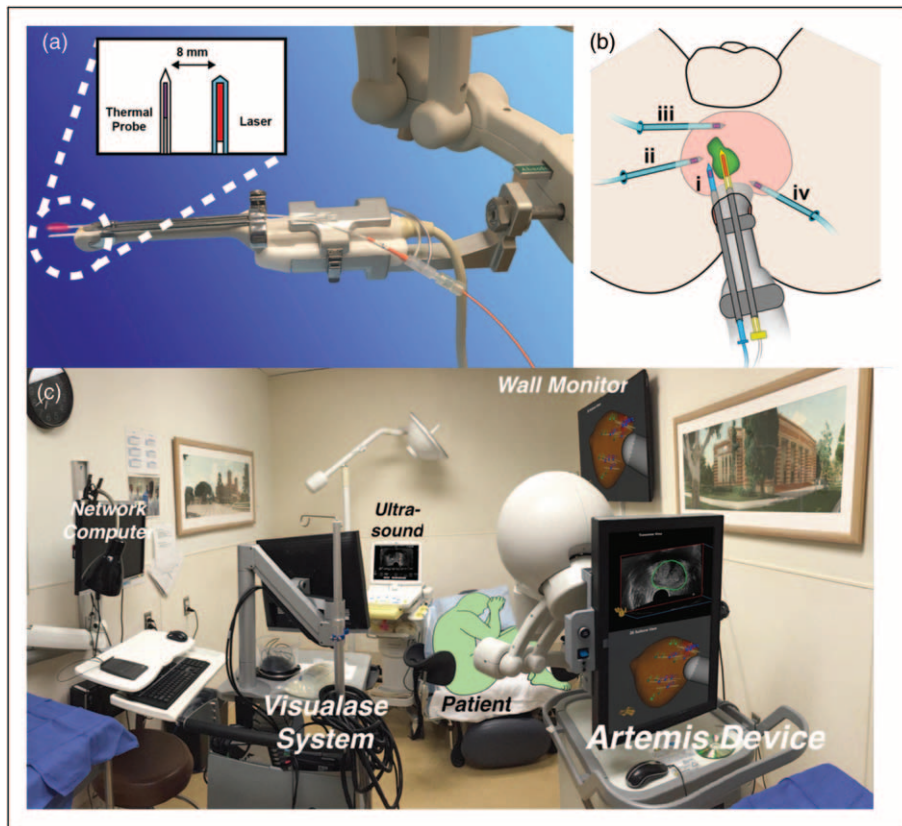
Although in-bore FLA is generally well tolerated and has short-term oncologic efficacy, it is cumbersome, expensive, and requires conscious sedation or general anesthesia. To address these challenges, the UCLA group has begun to perform FLA in the clinic setting under local anesthesia. MR/US fusion technology allows for accurate lesion targeting, and

**Table 2.** Published clinical trials reporting outcomes after focal laser ablation for prostate cancer

Study	Year	Approach	Anesthesia	N (patients)	Eligibility criteria	Length follow-up (months)	Biopsy results		
							Presence of CaP in ablation zone	Presence of CaP anywhere	Re-Biopsy Technique
Lindner <i>et al.</i> [44], University of Toronto	2009	In OR; MR/US fusion guidance	General	12	GS $\leq$ 6, PSA < 10 ng/ml, $\leq$ T2a	6	33% (4/12) All GS 6	50% (6/12) All GS 6	TRUS-guided 10 cores systematic + 2 cores cognitive targeting of ablation zone
Oto <i>et al.</i> [45], University of Chicago	2013	In-bore	Conscious sedation	9	GS $\leq$ 7, PSA < 10 ng/ml, $\leq$ T2a	6	22% (2/9) All GS 6	NR	In-bore MR-guided (2–3 cores)
Lepor <i>et al.</i> [77], New York University	2015	In-bore	Conscious sedation	25	GS $\leq$ 7, PSA < 10 ng/ml, $\leq$ T2a	3	4% (2/28) 1 pt w/GS 3+4 1 pt w/HGPIN	NR	In-bore MR-guided or MR/US fusion (3–4 cores)
Eggner <i>et al.</i> [46], University of Chicago	2016	In-bore	Conscious sedation	27	GS $\leq$ 7, PSA $\leq$ 15 ng/ml, PSAD $\leq$ 0.15 ng/cc, $\leq$ T2a	12	3-month f/u: 4% (1/27) 1 pt w/GS 6	12-month f/u: 40% (11/27) 2 pts w/GS 3+4:	3-month f/u: In-bore MR-guided of ablation zone (2 cores)
Natarajan <i>et al.</i> [47], UCLA	2016	In-bore	Conscious sedation and local	8	GS $\leq$ 3+4; $\leq$ T2b	6	12-month f/u: 11% (3/27) 1 pt w/GS 3+4	75% (6/8) at treatment margin 3 pts w/GS >3+4	12-month f/u: 12-core TRUS-guided systematic
Natarajan <i>et al.</i> [48], UCLA	2017	In clinic; MR/US fusion guidance	Local	10	GS $\leq$ 3+4; $\leq$ T2b	12	40% (4/10) All GS >6	7/10 (70%) 4 pts w/GS >6	MR/US fusion targeted + systematic on treatment side

CaP, prostate cancer; F/u, follow-up; GS, Gleason score; MR/US, magnetic resonance/ultrasound; PSA, prostate-specific antigen; PSAD, prostate-specific antigen density; Pts, patients; TRUS, trans-rectal ultrasound.





**FIGURE 1.** Focal laser ablation of prostate cancer in clinic setting [48<sup>\*\*\*</sup>]. (a) Insertion device. Fixed arm of Artemis fusion device allows stable positioning of laser fiber and thermal probe during treatment. Thermal probe, parallel to laser fiber, provides real-time monitoring of treatment temperature. (b) Probe placement. Transrectal ultrasound probe with laser fiber and parallel thermal probe (i) are diagrammed. Thermal probes (ii–iv) are placed via transperineal approach. Thermal probes continuously monitor intraprostatic temperature during procedure. Transrectal thermal probe (i) reads temperature changes at laser tip; transperineal probes (ii–iv) monitor safety. Green shape indicates tumor. (c) Room set-up in clinic for out-of-bore FLA. Patient (green) is in left lateral decubitus position. Operator sits at foot of table, surrounded by the MR/US fusion device (Artemis device), laser controls (Visualase System), and thermal probe monitor. Wall monitor allows all involved to observe procedure. Typically, temperature nearest laser tip reaches 50–60°C, and other thermal probes show little temperature change [48<sup>\*\*\*</sup>].

thermal probe monitoring can dependably replace MR thermometry to measure intra-prostatic temperature changes [48<sup>\*\*\*</sup>].

In-clinic FLA was first performed by Natarajan *et al.* [48<sup>\*\*\*</sup>] in 2017 in a phase I trial of 10 men with intermediate-risk CaP diagnosed by MR/US fusion biopsy. Positive biopsy locations were stored in 3D in the fusion device and used for transrectal laser fiber positioning during FLA. Transperineal and transrectal thermal probes were used for real-time thermometry (Fig. 1).

Results were promising. MRI taken 2 h post-FLA showed an ablation zone overlying the original region of interest. Urinary and erectile function were unaffected at 6-month follow-up. The procedure was tolerable under local anesthesia without need for narcotics. Biopsy results at 6-month follow-up revealed three patients with no residual cancer, three

with microfocal Gleason score 6 at the treatment zone or margin, and four with persistent clinically significant disease at the treatment zone or margin. Future trials will be necessary to refine and optimize oncologic outcomes with in-clinic FLA, developing a viable option for men with intermediate risk disease that minimizes the lifestyle implications of extirpative treatment and risks of anesthesia.

### High-intensity focused ultrasound

HIFU was first approved for prostate tissue ablation by the U.S. FDA in October 2015 [49]. HIFU may be used to ablate target tissue via high-intensity ultrasonic waves that cause both coagulative necrosis through heat and inertial cavitation from mechanical stress [50]. It is administered through a trans-rectal probe, which allows for

simultaneous treatment and real-time ultrasonic visualization of prostatic tissue. Tissue effect during HIFU treatment is usually measured by changes in refractive index; experimentally, MR thermometry has been used for thermal monitoring [51–54].

Originally used for whole-gland ablation, HIFU is now gaining acceptance as a focal therapy option, with reasonable oncologic outcomes. Partial-gland HIFU has been studied in several trials, with cancer-free rates as high as 95% on repeat biopsy of the ablation zone [55–58,59<sup>a</sup>,60<sup>a</sup>,61,62<sup>a</sup>]. Ninety-three percent metastasis-free survival, 58% biochemical recurrence-free survival (using Phoenix criteria), and 100% cancer-specific survival have been reported with over 5 years of follow-up [56,57]. Continence and erectile function rates are 90–100% and 77–100%, respectively. Serious complications from focal HIFU are rare compared to whole-organ treatments [55,63].

## Cryotherapy

Like HIFU, cryotherapy was originally used for whole-gland therapy and was later adapted for focal therapy [64]. Cryotherapy was the first modality used for focal therapy to treat unilateral disease while sparing the contralateral neurovascular bundle [65]. Since then, it has become one of the most commonly used focal therapy options for men with localized prostate cancer.

Cryotherapy involves transperineally inserting cryoprobes under TRUS guidance into the prostate region of interest and freezing this tissue to  $-40^{\circ}\text{C}$ , causing coagulative necrosis and ischemia. TRUS allows real-time visualization of the ice ball, allowing for dynamic estimation of margin control.

Long-term follow-up studies of men undergoing focal cryotherapy have been published in the past decade [66–76]. With 26 months median follow-up (range 12–70 months), cancer on biopsy was detected in 2–14% of patients in the treated hemi-ablation zone. All but one study relied on TRUS-guided prostate biopsies (one used transperineal template mapping biopsy [72]), and one employed mpMRI for lesion localization prior to cryotherapy [73]. 81–97% treatment-free survival and 100% overall- and cancer-specific survival are reported, with no metastases [66–69,71–74,76]. Pad-free continence ranged from 98 to 100%, and erectile function was preserved in 58–89% of men.

## CONCLUSION

MR-guided targeted biopsy offers major advantages over conventional US-guided biopsy in diagnosing

prostate cancer. Focal therapy, which depends on the information from the targeted biopsy method, appears to be gaining traction as an option for some men with prostate cancer. Appropriate patient selection and posttreatment results will be important subjects for future studies comparing long-term outcomes of focal and whole-gland therapy.

## Acknowledgements

None.

## Financial support and sponsorship

*This work was supported in part by the National Cancer Institute (R01CA158627), UCLA CTSI (UL1TR000124), the Jean Perkins Foundation, the Kent Kresa Family Foundation, and the Steven C. Gordon Family Foundation. The content is solely the responsibility of the authors and does not necessarily represent the official views of the National Cancer Institute or National Institutes of Health.*

## Conflicts of interest

*There are no conflicts of interest.*

## REFERENCES AND RECOMMENDED READING

Papers of particular interest, published within the annual period of review, have been highlighted as:

- of special interest
- of outstanding interest

1. Siegel RL, Miller KD, Jemal A. Cancer statistics, 2017. *CA Cancer J Clin* 2017; 67:7–30.
2. Welch HG, Fisher ES, Gottlieb DJ, Barry MJ. Detection of prostate cancer via biopsy in the medicare-SEER population during the PSA era. *JNCI J Natl Cancer Inst* 2007; 99:1395–1400.
3. Berglund RK, Masterson TA, Vora KC, *et al.* Pathological upgrading and up staging with immediate repeat biopsy in patients eligible for active surveillance. *J Urol* 2008; 180:1964–1967.
4. El Hajj A, Ploussard G, de la Taille A, *et al.* Analysis of outcomes after radical prostatectomy in patients eligible for active surveillance (PRIAS). *BJU Int* 2013; 111:53–59.
5. Dinh KT, Mahal BA, Ziehr DR, *et al.* Incidence and predictors of upgrading and up staging among 10,000 contemporary patients with low risk prostate cancer. *J Urol* 2015; 194:343–349.
6. de Rooij M, Hamoen EHJ, Witjes JA, *et al.* Accuracy of magnetic resonance imaging for local staging of prostate cancer: a diagnostic meta-analysis. *Eur Urol* 2016; 70:233–245.
7. Hricak H, Williams R, Spring D, *et al.* Anatomy and pathology of the male pelvis by magnetic resonance imaging. *Am J Roentgenol* 1983; 141:1101–1110.
8. Felker ER, Margolis DJ, Nassiri N, Marks LS. Prostate cancer risk stratification
  - with magnetic resonance imaging. *Urol Oncol Semin Orig Investig* 2016; 34:311–319.

A comprehensive review on the role of mpMRI in prostate cancer staging, operative planning, and active surveillance

9. Le JD, Stephenson S, Brugger M, *et al.* Magnetic resonance imaging-ultrasound fusion biopsy for prediction of final prostate pathology. *J Urol* 2014; 192:1367–1373.
10. Thompson JE, Moses D, Shnier R, *et al.* Multiparametric magnetic resonance imaging guided diagnostic biopsy detects significant prostate cancer and could reduce unnecessary biopsies and over detection: a prospective study. *J Urol* 2014; 192:67–74.
11. Woo S, Suh CH, Kim SY, *et al.* Diagnostic performance of prostate imaging reporting and data system version 2 for detection of prostate cancer: a systematic review and diagnostic meta-analysis. *Eur Urol* 2017; 72:177–188.
12. Rosenkrantz AB, Verma S, Choyke PL, *et al.* Prostate MRI and MRI-targeted
  - biopsy in patients with prior negative biopsy. *Am Urol Assoc - Guide* 2016; Available at: <http://www.auanet.org/guidelines/prostate-mri-and-mri-targeted-biopsy>.

The 'White Paper' detailing the joint recommendation for MR-guided prostate biopsy in the repeat biopsy setting by the American Urological Association and Society of Abdominal Radiology.

13. Ahmed HU, El-Shater Bosaily A, Brown LC, *et al.* Diagnostic accuracy of multiparametric MRI and TRUS biopsy in prostate cancer (PROMIS): a paired validating confirmatory study. *Lancet* 2017; 389:815–822.
- A landmark study endorsing the use of mpMRI in biopsy-naïve men as a triage tool to avoid unnecessary prostate biopsy.
14. D'Amico AV, Tempany CM, Cormack R, *et al.* Transperineal magnetic resonance image guided prostate biopsy. *J Urol* 2000; 164:385–387.
15. Wegelin O, van Melick HHE, Hooft L, *et al.* Comparing three different techniques for magnetic resonance imaging-targeted prostate biopsies: a systematic review of in-bore versus magnetic resonance imaging-transrectal ultrasound fusion versus cognitive registration. Is there a preferred technique? *Eur Urol* 2017; 71:517–531.
16. Siddiqui MM, Rais-Bahrami S, Turkbey B, *et al.* Comparison of MR/ultrasound fusion-guided biopsy with ultrasound-guided biopsy for the diagnosis of prostate cancer. *JAMA* 2015; 313:390–397.
17. Filson CP, Natarajan S, Margolis DJA, *et al.* Prostate cancer detection with magnetic resonance-ultrasound fusion biopsy: the role of systematic and targeted biopsies. *Cancer* 2016; 122:884–892.
- A study affirming the role of MR/US fusion biopsy in detecting high-grade prostate cancer and the importance of combining systematic and targeted biopsy for optimal cancer diagnosis. It also demonstrated that mpMRI region of interest grade and PSA density are significantly correlated with detection of clinically significant prostate cancer.
18. Valerio M, Donaldson I, Emberton M, *et al.* Detection of clinically significant prostate cancer using magnetic resonance imaging-ultrasound fusion targeted biopsy: a systematic review. *Eur Urol* 2015; 68:8–19.
19. Natarajan S, Marks LS, Margolis DJA, *et al.* Clinical application of a 3D ultrasound-guided prostate biopsy system. *Urol Oncol Semin Orig Investig* 2011; 29:334–342.
20. Cooperberg MR, Carroll PR. Trends in management for patients with localized prostate cancer. *JAMA* 2015; 314:80–82.
21. Hu JC, Chang E, Natarajan S, *et al.* Targeted prostate biopsy to select men for active surveillance: do the Epstein criteria still apply? *J Urol* 2014; 192:385–390.
22. Chang E, Jones TA, Natarajan S, *et al.* Value of tracking biopsy in men undergoing active surveillance of prostate cancer. *J Urol* 2017; 0. [Epub ahead of print]
- This study highlights the utility of tracking in MR/US fusion biopsy in active surveillance, enabling re-sampling of cancerous lesions to monitor for progression.
23. Palapattu GS, Salami SS, Cani AK, *et al.* Molecular profiling to determine clonality of serial magnetic resonance imaging/ultrasound fusion biopsies from men on active surveillance for low-risk prostate cancer. *Clin Cancer Res* 2017; 23:985–991.
- A study showing MR/US fusion biopsy can re-sample the same clonal focus of prostate cancer over time, confirmed at the molecular level.
24. Lee MC, Dong F, Stephenson AJ, *et al.* The Epstein criteria predict for organ-confined but not insignificant disease and a high likelihood of cure at radical prostatectomy. *Eur Urol* 2010; 58:90–95.
25. Patel HD, Tosoian JJ, Carter HB, *et al.* Adverse pathologic findings for men electing immediate radical prostatectomy. *JAMA Oncol* 2017; 70:760–766.
26. Frye TP, George AK, Kilchevsky A, *et al.* Magnetic resonance imaging-transrectal ultrasound guided fusion biopsy to detect progression in patients with existing lesions on active surveillance for low and intermediate risk prostate cancer. *J Urol* 2017; 197:640–646.
27. Recabal P, Assel M, Sjoberg DD, *et al.* The efficacy of multiparametric magnetic resonance imaging and magnetic resonance imaging targeted biopsy in risk classification for patients with prostate cancer on active surveillance. *J Urol* 2016; 196:374–381.
28. Tran GN, Leapman MS, Nguyen HG, *et al.* Magnetic resonance imaging-ultrasound fusion biopsy during prostate cancer active surveillance. *Eur Urol* 2016; 72:275–281.
29. Alberts AR, Roobol MJ, Drost F-JH, *et al.* Risk-stratification based on magnetic resonance imaging and prostate-specific antigen density may reduce unnecessary follow-up biopsy procedures in men on active surveillance for low-risk prostate cancer. *BJU Int* 2017. [Epub ahead of print]
30. Venderink W, van Luijtelar A, Bomers JGR, *et al.* Results of targeted biopsy in men with magnetic resonance imaging lesions classified equivocal, likely or highly likely to be clinically significant prostate cancer. *Eur Urol* [Internet] 2017. [Epub ahead of print]
31. Ma TM, Tosoian JJ, Schaeffer EM, *et al.* The Role of multiparametric magnetic resonance imaging/ultrasound fusion biopsy in active surveillance. *Eur Urol* 2016; 71:174–180.
32. Ouzzane A, Renard-Penna R, Marliere FO, *et al.* Magnetic resonance imaging targeted biopsy improves selection of patients considered for active surveillance for clinically low risk prostate cancer based on systematic biopsies. *J Urol* 2015; 194:350–356.
33. Dall'Era MA, Albertsen PC, Bangma C, *et al.* Active surveillance for prostate cancer: a systematic review of the literature. *Eur Urol* 2012; 62:976–983.
34. Elkhoury FF, Simopoulos DN, Marks LS. Targeted prostate biopsy in the era of active surveillance. *Urology* 2017. [Epub ahead of print]
35. Wise AM, Stamey TA, McNeal JE, Clayton JL. Morphologic and clinical significance of multifocal prostate cancers in radical prostatectomy specimens. *Urology* 2002; 60:264–269.
36. Villers A, McNeal JE, Freiha FS, Stamey TA. Multiple cancers in the prostate. Morphologic features of clinically recognized versus incidental tumors. *Cancer* 1992; 70:2313–2318.
37. Stamey TA, McNeal JM, Wise AM, Clayton JL. Secondary cancers in the prostate do not determine PSA biochemical failure in untreated men undergoing radical retropubic prostatectomy. *Eur Urol* 2001; 39(Suppl 4):22–23.
38. Ahmed HU. The index lesion and the origin of prostate cancer. *N Engl J Med* 2009; 361:1704–1706.
39. Liu W, Laitinen S, Khan S, *et al.* Copy number analysis indicates monoclonal origin of lethal metastatic prostate cancer. *Nat Med* 2009; 15:559–565.
40. Donaldson IA, Alonzi R, Barratt D, *et al.* Focal therapy: patients, interventions, and outcomes—a report from a consensus meeting. *Eur Urol* 2015; 67:771–777.
41. Klotz L. Active surveillance and focal therapy for low-intermediate risk prostate cancer. *Transl Androl Urol* 2015; 4:342–354.
42. Nassiri N, Chang E, Lieu P, *et al.* Focal therapy eligibility determined by MRI/US fusion biopsy. *J Urol* 2017; Available at: <https://www.ncbi.nlm.nih.gov/pubmed/28830754>.
43. Perera M, Krishnananthan N, Lindner U, Lawrentschuk N. An update on focal therapy for prostate cancer. *Nat Publ Gr* [Internet] 2016; 13:641–653.
44. Lindner U, Weersink RA, Haider MA, *et al.* Image guided photothermal focal therapy for localized prostate cancer: phase I trial. *J Urol* 2009; 182:1371–1377.
45. Oto A, Sethi I, Karczmar G, *et al.* MR imaging – guided focal laser ablation for prostate cancer: phase I trial. *Radiology* 2013; 267:23440319.
46. Eggener SE, Yousof A, Watson S, *et al.* Phase II evaluation of magnetic resonance imaging guided focal laser ablation of prostate cancer. *J Urol* 2016; 196:.
- A study using in-bore focal laser ablation of prostate cancer, demonstrating safety and good short-term oncologic outcomes
47. Natarajan S, Raman S, Priester AM, *et al.* Focal laser ablation of prostate cancer: phase I clinical trial. *J Urol* 2016; 196:68–75.
- A study of in-bore focal laser ablation of prostate cancer, demonstrating safety and feasibility of FLA and importance of assessing ablation margins for residual cancer.
48. Natarajan S, Jones TA, Priester AM, *et al.* Focal laser ablation of prostate cancer: feasibility of magnetic resonance imaging-ultrasound fusion for guidance. *J Urol* 2017; 198:839–847.
- First study of FLA done in clinic setting under local anesthesia.
49. Jones TA, Chin J, Mcleod D, *et al.* High intensity focused ultrasound for radio-recurrent prostate cancer: a North American clinical trial. *J Urol* 2017; Available at: <https://www.ncbi.nlm.nih.gov/pubmed/28652121>.
50. Kennedy JE. Innovation: high-intensity focused ultrasound in the treatment of solid tumours. *Nat Rev Cancer* 2005; 5:321–327.
51. Hectors SJCG, Jacobs I, Strijkers GJ, Nicolay K. Multiparametric MRI analysis for the identification of high intensity focused ultrasound-treated tumor tissue. Gelovani JG, editor. *PLoS One*. 2014 Jun 13.
52. Napoli A, Anzidei M, De Nunzio C, *et al.* Real-time magnetic resonance-guided high-intensity focused ultrasound focal therapy for localised prostate cancer: preliminary experience. *Eur Urol* 2013; 63:395–398.
53. Hectors SJCG, Jacobs I, Moonen CTW, *et al.* MRI methods for the evaluation of high intensity focused ultrasound tumor treatment: Current status and future needs. *Magn Reson Med* 2016; 75:302–317.
54. Ghal S, Louis AS, Van Vliet M, *et al.* Real-time MRI-guided focused ultrasound for focal therapy of locally confined low-risk prostate cancer: feasibility and preliminary outcomes. *Am J Roentgenol* 2015; 205:W177–W184.
55. Ahmed HU, Freeman A, Kirkham A, *et al.* Focal therapy for localized prostate cancer: a phase I/II trial. *J Urol* 2011; 185:1246–1255.
56. El Fegoun AB, Barret E, Prapotnich D, *et al.* Focal therapy with high-intensity focused ultrasound for prostate cancer in the elderly. A feasibility study with 10 years follow-up. *Int Braz J Urol* 2017. ;37(2):213-9-2.
57. van Velthoven R, Aoun F, Marcelis C, *et al.* A prospective clinical trial of HIFU hemiablation for clinically localized prostate cancer. *Prostate Cancer Prostatic Dis* 2016; 19:79–83.
58. Ahmed HU, Dickinson L, Charman S, *et al.* Focal ablation targeted to the index lesion in multifocal localised prostate cancer: a prospective development study. *Eur Urol* 2015; 68:927–936.
59. Feijoo ERC, Sivaraman A, Barret E, *et al.* Focal high-intensity focused ultrasound targeted hemiablation for unilateral prostate cancer: a prospective evaluation of oncologic and functional outcomes. *Eur Urol* 2016; 69:214–220.
- A study of prostate HIFU hemi-ablation for prostate cancer, demonstrating acceptable oncologic outcomes at 12 months follow-up with preserved quality of life and no significant adverse events
60. Rischmann P, Gelet A, Riche B, *et al.* Focal high intensity focused ultrasound of unilateral localized prostate cancer: a prospective multicentric hemiablation study of 111 patients. *Eur Urol* 2017; 71:267–273.
- A multiinstitutional study of HIFU hemiablation for prostate cancer showing good oncologic outcomes, safety of HIFU hemiablation, and preserved quality of life.
61. Ahmed HU, Hindley RG, Dickinson L, *et al.* Focal therapy for localised unifocal and multifocal prostate cancer: a prospective development study. *Lancet Oncol* 2012; 13:622–632.



62. Garcia-Barreras S, Sanchez-Salas R, Sivaraman A, *et al.* Partial gland ablation versus radical prostatectomy comparative analysis of partial gland ablation and radical prostatectomy to treat low- and intermediate-risk prostate cancer: oncologic and functional outcomes. *J Urol* 2017; Available at: <https://www.ncbi.nlm.nih.gov/pubmed/28823768>.
- A study comparing oncologic outcomes between partial gland ablation with HIFU and cryotherapy to radical robot-assisted radical prostatectomy, demonstrating good oncologic control and few adverse effects with partial gland ablation.
63. Netsch C, Bach T, Gross E, Gross AJ. Rectourethral fistula after high-intensity focused ultrasound therapy for prostate cancer and its surgical management. *Urology* 2011; 77:999–1004.
64. Gonder MJ, Soanes WA, Shulman S. Cryosurgical treatment of the prostate. *Invest Urol* 1966; 3:372–378.
65. Onik G, Narayan P, Vaughan D, *et al.* 'Focal nerve-sparing' cryosurgery for treatment of primary prostate cancer: A new approach to preserving potency. *Urology* 2002; 60:109–114.
66. Bahn DK, Silverman P, Lee F, *et al.* Focal prostate cryoablation: initial results show cancer control and potency preservation. *J Endourol* 2006; 20: 688–692.
67. Onik G, Vaughan D, Lotenfoe R, *et al.* Male lumpectomy': focal therapy for prostate cancer using cryoablation. *Urology* 2007; 70:S16–21.
68. Ellis DS, Manny TB, Rewcastle JC. Focal cryosurgery followed by penile rehabilitation as primary treatment for localized prostate cancer: initial results. *Urology* 2007; 70:S9–15.
69. Truesdale MD, Cheetham PJ, Hruby GW, *et al.* An evaluation of patient selection criteria on predicting progression-free survival after primary focal unilateral nerve-sparing cryoablation for prostate cancer. *Cancer J* 2010; 16:544–549.
70. Ward JF, Jones JS. Focal cryotherapy for localized prostate cancer: a report from the national Cryo On-Line Database (COLD) Registry. *BJU Int* 2012; 109:1648–1654.
71. Bahn D, de Castro Abreu AL, Gill IS, *et al.* Focal cryotherapy for clinically unilateral, low-intermediate risk prostate cancer in 73 men with a median follow-up of 3.7 years. *Eur Urol* 2012; 62:55–63.
72. Hale Z, Miyake M, Palacios DA, Rosser CJ. Focal cryosurgical ablation of the prostate: a single institute's perspective. *BMC Urol* 2013; 13:2.
73. Durand M, Barret E, Galiano M, *et al.* Focal cryoablation: a treatment option for unilateral low-risk prostate cancer. *BJU Int* 2014; 113:56–64.
74. Barqawi AB, Stoimenova D, Krughoff K, *et al.* Targeted focal therapy for the management of organ confined prostate cancer. *J Urol* 2014; 192:749–753.
75. Mendez MH, Passoni NM, Pow-Sang J, *et al.* Comparison of outcomes between preoperatively potent men treated with focal versus whole gland cryotherapy in a matched population. *J Endourol* 2015; 29:1193–1198.
76. Lian H, Zhuang J, Yang R, *et al.* Focal cryoablation for unilateral low-intermediate-risk prostate cancer: 63-month mean follow-up results of 41 patients. *Int Urol Nephrol* 2016; 48:85–90.
77. Lepor H, Llukani E, Sperling D, Fütterer JJ. Complications, recovery, and early functional outcomes and oncologic control following in-bore focal laser ablation of prostate cancer. *Eur Urol* 2015; 68:924–926.